


Dorsal Forebrain Anomaly in Williams Syndrome



Albert M. Galaburda, MD; J. Eric Schmitt, BS; Scott W. Atlas, MD; Stephan Eliez, MD; Ursula Bellugi, EdD; Allan L. Reiss, MD

Background: Williams syndrome (WMS) is a rare neurogenetic condition with a behavioral phenotype that suggests a dorsal and/or ventral developmental dissociation, with deficits in dorsal but not the ventral hemispheric visual stream. A shortened extent of the dorsal central sulcus has been observed in autopsy specimens.

Objective: To compare gross anatomical features between the dorsal and ventral portions of the cerebral hemispheres by examining the dorsal extent of the central sulcus in brain magnetic resonance images from a sample of subjects with WMS and age- and sex-matched control subjects.

Subjects: Twenty-one subjects having clinically and genetically diagnosed WMS (mean±SD age, 28.9±7.9 years) were compared with 21 age- and sex-matched typically developing controls (mean±SD age, 28.8±7.9 years).

Design: High-resolution structural magnetic resonance images were acquired. The extent of the central sulcus was qualitatively assessed via surface projections of the cerebral cortex.

Results: The dorsal central sulcus is less likely to reach the interhemispheric fissure in subjects with WMS than in controls for both left ($P<.001$, $\chi^2=15.79$) and right ($P<.001$, $\chi^2=12.95$) hemispheres. No differences between the groups were found in the ventral extent of the central sulcus.

Conclusions: Anomalies in the dorsal region in patients with WMS are indicative of early neurodevelopmental problems affecting the development of the dorsal forebrain and are most likely related to the deficits in visuospatial ability and behavioral timing often observed in this condition.

Arch Neurol. 2001;58:1865-1869

From the Division of Behavioral Neurology, Department of Neurology, Beth Israel-Deaconess Medical Center and Harvard Medical School, Boston, Mass (Dr Galaburda); Stanford Psychiatry Neuroimaging Laboratory, Department of Psychiatry and Behavioral Sciences (Mr Schmitt and Drs Eliez and Reiss) and the Division of Neuroradiology, Department of Radiology (Dr Atlas), Stanford University School of Medicine, Stanford, Calif; and the Laboratory for Cognitive Neuroscience, Salk Institute for Biological Studies, La Jolla, Calif (Dr Bellugi).

EVEN BEFORE Gall and Spurzheim, Luigi Rolando, professor of anatomy in Sardinia after whom the central sulcus is named, called attention to the relationship between cortical folding and function in the human brain.¹ In this article we compare the fissure of Rolando in Williams syndrome (WMS) and control brains with the goal of better understanding the neural basis of abnormal cognitive function in WMS. Williams syndrome is a mental retardation syndrome associated with a hemideletion in the long arm of chromosome 7 (7q11.23), which consists of a unique constellation of somatic, brain, and cognitive features.^{2,3} At least 15 genes are involved in the deletion and partial deletions with equally partial phenotypic manifestations of WMS. Approximately 1 in 25 000 births exhibit the deletion and accompanying phenotype.^{4,5} Our research has centered in part on the description of the neuroanatomical phenotype for the purpose

of linking, on the one hand, brain to physiology and behavior, and, on the other, to the genomic anomaly. The anatomical research in our laboratories is driven by a general hypothesis derived from the analysis of behaviors patients with WMS exhibit.^{3,6} Namely, these patients, whose mental retardation is equivalent in range to that seen in Down syndrome, show an unusual and uneven neuropsychological profile. This consists of deficits in processing visuospatial tasks, relative preservation of many aspects of language, a preserved ability to process human faces, an unusual personality characterized by lack of fear of strangers, highly affective speech, occasionally inappropriate friendliness, and a great deal of interest in and often remarkable ability for things musical.^{3,6,7}

The best neuroanatomical fit for the constellation of behavioral findings seen in WMS appears to be the primary involvement of the dorsal portions of the hemispheres, which in the caudal half of the brain are concerned with representation

SUBJECTS AND METHODS

SUBJECTS

Twenty-one subjects (12 women and 9 men) diagnosed as having WMS (mean \pm SD age, 28.9 \pm 7.9 years; age range, 19-44 years) were compared with 21 healthy control subjects individually matched for age and sex (mean \pm SD age, 28.8 \pm 7.9 years; age range, 19-48 years). Both groups were recruited by the Laboratory for Cognitive Neuroscience at the Salk Institute for Biological Studies, La Jolla, Calif. Diagnoses of WMS were determined genetically by fluorescent in situ hybridization probes for elastin, a gene consistently found in the critical deletion region associated with WMS.^{4,5} All diagnoses were confirmed by a medical geneticist. Controls were typically developing individuals without evidence of psychiatric or neurologic disorder.

Each subject gave informed consent for their participation in the study via consent forms that were approved by the institutional review board at the Salk Institute for Biological Studies. Some of the subjects with WMS in this study have been described in other neuroimaging studies.²²⁻²⁴

RADIOLOGIC IMAGING

Magnetic resonance images of each subject's brain were acquired with a 1.5-T scanner (GE-Signa; General Electric, Milwaukee, Wis). Contiguous sagittal images were acquired with a 3-dimensional volumetric radio frequency spoiled gradient echo-pulse sequence using the following scan parameters: repeat time, 24 milliseconds; echo time, 5 milliseconds; flip angle, 45°; number of excitations, 2; acquisition matrix size, 256 \times 192 pixels; field of view, 240 mm; slice thickness, 1.2 mm; and 124 slices. All scans from the subjects with WMS and 26 of the 28 control scans were acquired at the University of California, San Diego Medical Center Magnetic Resonance Imaging Institute.

Two normal control subjects were scanned at Stanford University, Stanford, Calif, using an identical pulse sequence and scanner.

The spoiled gradient echo-pulse sequence image data were imported into the program BrainImage²⁵ for semiautomated removal of nonbrain tissue.²⁶ The images were then cut into cubic voxels using a Catmull-Rom reslice algorithm²⁶ and then subsequently rotated into Talairach space.²⁷ Each subject's skull-stripped image was rendered via a ray-tracing algorithm built into the BrainImage environment. The spatial location of each view used for rating the dorsal central sulcus was standardized as a superior view (looking down on the superior cortical surface from above, **Figure 1**), while ratings for the ventral central sulcus were performed on standardized lateral views made at 90° lateral to the superior view. Oblique surface views at 45° to the left and right of the superior view also were made.

Two experts in neuroanatomical imaging (A.M.G. and S.W.A.) were asked to identify the central sulcus in each image and determine whether it extended fully to the interhemispheric fissure. All rating for the dorsal central sulcus occurred on the superior view; the lateral views were used only to confirm the identity of the central sulcus when the superior view was ambiguous. Both raters were blinded to the identities and diagnosis of the subjects. Interrater and intrarater reliability was determined in 20 data sets via the κ statistic. The interrater value was 0.80, while intrarater reliability (for A.M.G.) was 0.86. As a contrast to the dorsal measure, one of us (A.M.G.) also determined whether the ventral central sulcus met the sylvian fissure using the lateral views provided.

DATA ANALYSIS

Simple χ^2 tests were performed to understand the effect of diagnosis on right and left central sulcus morphologic features. The effects of both diagnosis and sex were also examined. Statistical significance was set at $P = .05$.

and processing of visuospatial information⁸⁻¹⁰ and in the frontal lobes with, among other things, the on-off timing of behavior.¹¹ By contrast, behaviors associated with the ventral and perisylvian portions of the hemispheres, concerned with many aspects of language,¹²⁻¹⁴ object properties of visual and other stimuli,¹⁵⁻¹⁷ and programs for the performance of various motor behaviors (eg, speech^{18,19}) appear to be at least relatively spared in WMS. However, individuals with WMS are often gregarious and speak excessively,⁶ which, again, could reflect abnormality in the dorsomedial frontal lobe. The attention disorder often seen in WMS, with attention-deficit rates reported at 4 times those of the normal population, also implicates the dorsomedial frontal cortex.^{20,21}

Therefore, one part of the research in our laboratories has focused on comparing gross anatomical features between the dorsal and ventral portions of the cerebral hemispheres. Herein we report a finding involving the central sulcus. Specifically, after noticing that the central sulcus was too short in its dorsal extent in several autopsy specimens from brains of cases with WMS, by comparison to the investigators' own experience and published data,^{2,9} we examined the dorsal extent of the cen-

tral sulcus in brain magnetic resonance images from a sample of persons with WMS and age- and sex-matched control subjects.

RESULTS

Subjects with WMS were far less likely to have central sulci that reached the interhemispheric fissure than the control group (**Figure 2**). While 68% (14/21) of the control subjects' central sulci extended fully to the interhemispheric fissure, only 11% (2/21) did so in patients with WMS. This observation was statistically significant both for the right ($P < .001$; $\chi^2 = 12.95$) and left ($P < .001$; $\chi^2 = 15.79$) central sulci. The **Table** summarizes these results.

The dissimilarities between groups in the dorsal extent of the central sulcus were not observed on its ventral end. Overall, 13% (3/21) of the central sulci in controls reached the sylvian fissure compared with 14% (3/21) in subjects with WMS. Neither hemisphere was statistically significantly different between the 2 groups. No differences owing to sex were found in either group.

Before Vicq D'Azyr, graphic depictions of cortical folding are mostly chaotic, but even the latter does not endeavor to mark gyri and sulci on the median surface, other than the parieto-occipital sulcus. However, one can see in his drawing of the medial hemispheric surface the classic notch of the central sulcus, curled posteriorly and concaved upward, just anterior to the upward turn of the cingulate sulcus.²⁸ Later, Rolando draws the fissure on the lateral surface of the brain, where it is seen to be particularly short; it does not reach either the dorsal edge of the convexity or the sylvian fissure.²⁹ There are distortions in Rolando's drawing that suggest that the anatomist has taken a fair amount of license for the purpose of illustration. For instance, he spreads open the sylvian fossa to show the insula, thus, distorting perisylvian sulci. Also, he draws a circular gyrus around the medial edge of the hemisphere (cingulate gyrus), including frontal, parietal, occipital, and temporal edges, that might be the reason for which the central sulcus fails to reach all the way to the medial surface. Such gyrus has never been observed by others.

It is well recognized that there is a great deal of variability in the gross appearance of the central sulcus.³⁰ This variability is mostly in the shape of the sulcus at the surface of the brain (as opposed to the buried aspect of the sulcus), but length and extent also vary. For instance, Damasio³¹ finds that only 28% of brains show a central sulcus that reaches the sylvian fissure. Critchley³² cites a figure between 10% and 20%, whereas Cunningham³³ cites a figure of 19%. Damasio³¹ simply states that the sulcus arises from the interhemispheric fissure, implying that this is the rule. In the detailed description of the sulcus by Critchley,³² nothing is mentioned about the dorsal extent. Crosby et al describe the fissure as "beginning in the medial surface of the hemisphere."^{34(p344)} Eberstaller³⁵ reports that in nearly all cases the central sulcus reaches the medial surface, while this figure is placed at only 88% by Lang.³⁶ Additional information is gleaned from drawings and photographs accompanying the writings on this subject. For instance, the typical cuneiform head of the sulcus on the medial surface is seen in the drawings of Eberstaller.³⁵ Where the sulcus reaches over the dorsal hemispheric margin to continue on the medial surface, it indents the margin causing a depression that has been called the "crochet de Rolando" or "crochet Rolandique" by French authors.³⁰ This is also the case in the 4 hemispheres Damasio illustrates.³¹

Ono et al³⁰ present the most detailed modern description of the central sulcus. These authors state that in 20% of cases the central sulcus does not reach the dorsal margin of the hemisphere and that in some of these it ends in a bifurcation (a frequent pattern in WMS). However, when they present their data graphically, they report extension to the medial surface in 56% of the cases on the right hemisphere and 72% of the cases on the left hemisphere. Our figures are 55% (11/21) and 80% (17/21), respectively, in our control sample, which is consistent with Ono et al.³⁰

According to Ono et al the central sulcus does not usually reach the sylvian fissure, being separated from it

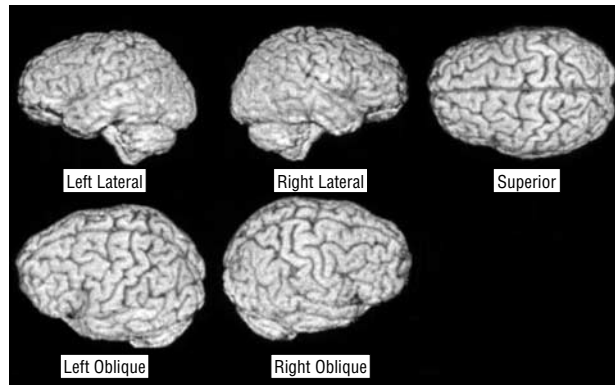


Figure 1. Standardized-rendered surface views demonstrating extent of the central sulcus. The superior view was used to judge whether the central sulcus met the interhemispheric fissure, while the lateral views were used to rate whether the central sulcus met the sylvian fissure. The oblique views were used only to help identify the central sulcus when the superior and lateral views were ambiguous.

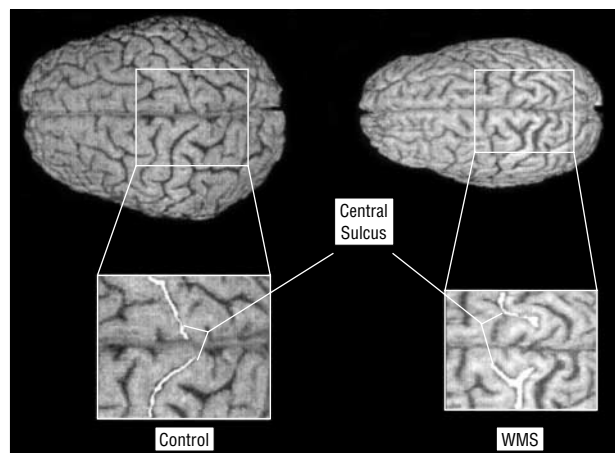


Figure 2. Characteristic neuroanatomy of Williams syndrome (WMS). The magnified views demonstrate the extent of the central sulcus (in white) as it approaches the interhemispheric fissure. Note that the control subject has central sulci that reach completely to the interhemispheric fissure and that curve slightly posteriorly, while the central sulci of the WMS-affected subject are separated by unusual gyral convolutions.

Shortened Extent of the Dorsal Central Sulcus in Patients With Williams Syndrome (WMS)*

Location	Patients With WMS, %	Control Subjects, %	P Value
Dorsal central sulcus			
Left	24 (5)	80 (17)	<.001
Right	0	55 (12)	<.001
Ventral central sulcus			
Left	5 (1)	5 (1)	>.99
Right	24 (5)	20 (4)	>.99

*Percentages (actual numbers) represent the frequency that the central sulcus met either the interhemispheric fissure (dorsal) or the sylvian fissure (ventral). Statistical significance values ($P < .05$) were calculated using the χ^2 test.

by a gyrus that connects the inferior ends of the precentral and postcentral gyri. This bridge is called the "pli de passage frontopariétal inférieur" or "opercule Rolandique." Ono et al report that the central sulcus reaches

all the way to the sylvian fissure in 16% of the cases, right or left hemispheres. Our figures are 13% (3/21) for controls and 14% (3/21) for patients with WMS, also without hemispheric differences. Illustrations by the classic authors are roughly equivalent.^{33,37}

During development, the central sulcus appears first on the convexity between the fifth and sixth gestational months and then approaches the dorsal margin of the hemisphere.³⁷ According to Retzius,³⁷ only 64% of fetal cases show full extension of the central sulcus to the medial surface. Chi et al³⁸ report that the sulcus first appears during the 20th week of gestation, but occasionally the right one is seen as early as the 17th week. No comment is made about the sulcus's relation to the interhemispheric fissure, but examination of the drawings presented with the text in Chi et al shows that the sulcus is still short of the midline at the end of the 31st week, arriving at the interhemispheric fissure between the 32nd and 35th weeks.

Similarly, there is little information we could gather on the anatomy of the central sulcus in nonhuman primates. In general, illustrations of the central sulcus in monkeys show a sulcus that does not reach the medial edge of the hemisphere or the sylvian fissure, whereas in the chimpanzee, it appears to reach the medial surface as in the human.³⁹⁻⁴²

In the present study we found that the central sulcus in WMS-affected subjects usually does not reach the medial surface of the brain. Overall (left and right hemispheres together), the sulcus reached the midline in 68% (14/21) of the control brains while this was true in only 11% (3/21) of WMS-affected brains. In the right hemisphere, the figures were 55% (11/21) and 0%, respectively, whereas in the left, they were 80% (17/21) and 24% (5/21). There were no differences between WMS-affected and control brains in the ventral extension of the central sulcus.

It might be wrongly said that the pattern of the central sulcus in WMS is generally ontogenetically immature and comparable to a developmental stage before 31 weeks' gestation because this judgment would apply only to the dorsal extent of the central sulcus, thus belying a regionalized maturational difference. Similarly unjustified would be the general conclusion that the finding reflects a primitive phylogenetic development, since the ventral portion of the sulcus does not differ between WMS-affected and control brains. Foreshortening dorsally could be the result of decreased development of the cortices surrounding the central sulcus itself—areas 4, 3, 1, and 2. In this case, dorsal foreshortening may imply changes in these functional-architectonic areas, which are involved in lower limb and trunk representation. More likely, however, or at least the preferred interpretation of these writers, the lack of opercularization of the dorsal extent of the central sulcus may reflect changes in overall dorsomedial opercularization of the hemispheres. Thus, expansion of dorsal cortices (eg, Brodmann areas 6, 8, 5, and 7) in the normal condition would have the effect of growth toward the dorsomedial cortex dorsally and into the frontal and parietal opercula ventrally, thus carrying the central sulcus with it in both directions. Relative lack of expansion of the homotypical cortices of the

frontal and parietal lobes would also explain the morphologic features of the central sulcus in fetal human brains and in nonhuman primates. Therefore, the relative lack of opercularization of the central sulcus dorsally but not ventrally would suggest that the problem in the WMS-affected brain is dorsal and not perisylvian, thus consistent with the behavioral findings. Ventral cortical functions, including object recognition, speech, and language, and even the excellent face recognition abilities seen in patients with WMS all relate to the ventral visual and cognitive pathways, whereas poor visuospatial function, hyperactivity, and lack of approach inhibition implicate the dorsal pathways. This interpretation makes the prediction that the superior parietal lobule measured directly and the superior frontal gyrus will be found to be smaller in WMS-affected brains compared with controls. This prediction is being tested in our laboratories.

Accepted for publication July 24, 2001.

This research was supported by National Institutes of Health grants HD33113 at the Salk Institute for Biological Studies (Dr Bellugi) and MH01142 and HD31715 (Dr Reiss). This work also was partially supported by a grant from the MIND (Music Intelligence Neural Development) Institute, University of California, Davis; the David and Lucille Packard Foundation, Los Altos, Calif, and the Sinclair Fund, Stanford (Dr Reiss).

We are grateful to the participants in these studies and to the local, regional, and national WMS associations. Special thanks to Julie Korenberg and David Feinstein for their advice and work that made the manuscript possible.

Corresponding author and reprints: Albert M. Galaburda, MD, Beth Israel-Deaconess Medical Center, 330 Brookline Ave, Boston, MA 02215 (e-mail: agalabur@caregroup.harvard.edu).

REFERENCES

1. Caputi F, Spaziante R, de Divitiis E, Nashold BS Jr. Luigi Rolando and his pioneering efforts to relate structure to function in the nervous system. *J Neurosurg.* 1995;83:933-937.
2. Bellugi U, Lichtenberger L, Mills D, Galaburda A, Korenberg JR. Bridging cognition, the brain and molecular genetics: evidence from Williams syndrome. *Trends Neurosci.* 1999;22:197-207.
3. Bellugi U, Lichtenberger L, Jones W, Lai Z, St George M. The neurocognitive profile of Williams syndrome: a complex pattern of strengths and weaknesses [review]. *J Cogn Neurosci.* 2000;12(suppl 1):7-29.
4. Korenberg J, Chen XN, Lai Z, Yimlamia D, Bisighini R, Bellugi U. Williams syndrome: the search for the genetic origins of cognition [abstract]. *Am J Hum Genet.* 1997;61:103.
5. Korenberg JR, Chen XN, Hirota H, et al. VI. Genome structure and cognitive map of Williams syndrome. *J Cogn Neurosci.* 2000;12(suppl 1):89-107.
6. Jones W, Bellugi U, Lai Z, et al. II. Hypersociability in Williams syndrome. *J Cogn Neurosci.* 2000;12(suppl 1):30-46.
7. Levitin D, Bellugi U. Musical abilities in individuals with Williams syndrome. *Musical Percept.* 1998;15:357-389.
8. Atkinson J, King J, Braddick O, Nokes L, Anker S, Braddick F. A specific deficit of dorsal stream function in Williams' syndrome. *Neuroreport.* 1997;8:1919-1922.
9. Galaburda AM, Bellugi UV. Multi-level analysis of cortical neuroanatomy in Williams syndrome. *J Cogn Neurosci.* 2000;12(suppl 1):74-88.
10. Shen L, Hu X, Yacoub E, Ugurbil K. Neural correlates of visual form and visual spatial processing. *Hum Brain Mapp.* 1999;8:60-71.
11. Niki H, Watanabe M. Prefrontal and cingulate unit activity during timing behavior in the monkey. *Brain Res.* 1979;171:213-224.

12. Damasio AR, Geschwind N. The neural basis of language. *Annu Rev Neurosci*. 1984;7:127-147.
13. Fiez JA, Raichle ME. Linguistic processing. *Int Rev Neurobiol*. 1997;41:233-254.
14. Raichle ME. What words are telling us about the brain [review]. *Cold Spring Harb Symp Quant Biol*. 1996;61:9-14.
15. Gauthier I, Tarr MJ, Moylan J, Skudlarski P, Gore JC, Anderson AW. The fusiform "face area" is part of a network that processes faces at the individual level. *J Cogn Neurosci*. 2000;12:495-504.
16. Biederman I, Gerhardstein PC, Cooper EE, Nelson CA. High-level object recognition without an anterior inferior temporal lobe. *Neuropsychologia*. 1997;35:271-287.
17. Sergent J, Ohta S, MacDonald B. Functional neuroanatomy of face and object processing: a positron emission tomography study. *Brain*. 1992;115(pt 1):15-36.
18. Paus T, Perry DW, Zatorre RJ, Worsley KJ, Evans AC. Modulation of cerebral blood flow in the human auditory cortex during speech: role of motor-to-sensory discharges. *Eur J Neurosci*. 1996;8:2236-2246.
19. Karis R, Horenstein S. Localization of speech parameters by brain scan. *Neurology*. 1976;26:226-233.
20. Morris CA, Demsey SA, Leonard CO, Dilts C, Blackburn BL. Natural history of Williams syndrome: physical characteristics. *J Pediatr*. 1988;113:318-326.
21. Finegan J, Sitarenios G, Smith M, Meschino W. Attention-deficit hyperactivity disorder in children with Williams syndrome: preliminary findings. Paper presented at: Williams Syndrome Association Annual Professional Conference; July 26, 1994; San Diego, Calif.
22. Reiss AL, Eliez S, Schmitt JE, et al. Neuroanatomy of Williams syndrome: a high-resolution MRI study. *J Cogn Neurosci*. 2000;12(suppl 1):65-73.
23. Schmitt JE, Eliez S, Bellugi U, Reiss AL. Analysis of cerebral shape in Williams syndrome. *Arch Neurol*. 2001;58:283-287.
24. Schmitt JE, Eliez S, Warsofsky IS, Bellugi U, Reiss AL. Corpus callosum morphology of Williams syndrome: relation to genetics and behavior. *Dev Med Child Neurol*. 2001;43:155-159.
25. Reiss A. *BrainImage*. Stanford, Calif: Stanford University; 2001.
26. Subramaniam B, Hennessey JG, Rubin MA, Beach LS, Reiss AL. Software and methods for quantitative imaging in neuroscience: the Kennedy Krieger Institute Human Brain Project. In: Koslow SH, Huerta MF, eds. *Neuroinformatics: An Overview of the Human Brain Project*. Hinsdale, NJ: Lawrence A Erlbaum Associates; 1997:335-360.
27. Talairach J, Tournoux P. *Co-Planar Stereotaxic Atlas of the Human Brain*. New York, NY: Thieme Medical Publishers Inc; 1988.
28. Vicq D'Azyr F. Recherches sur la structure du cerveau, du cervelet, de la moelle allongée, de la moelle épinière et sur l'origine des nerfs de l'homme et des animaux. In: *Memoires de l'Academie Royale, 1781*. Paris, France: Imprimerie Royale; 1784.
29. Rolando L. Della struttura degli emisferi cerebrali. *Memoria della Real Academia delle scienze di Torino*. Torino, Italy: Real Academia delle Scienze; 1831.
30. Ono M, Kubik S, Abernathy CD. *Atlas of the Cerebral Sulci*. New York, NY: Thieme Medical Publishers; 1990.
31. Damasio H. *Human Brain Anatomy in Computerized Images*. New York, NY: Oxford University Press; 1995.
32. Critchley M. *The Parietal Lobes*. New York, NY: Hafner Pub Co; 1966.
33. Cunningham DJ. *Contribution to the Surface Anatomy of the Cerebral Hemispheres*. Dublin, Ireland: Academy House; 1892.
34. Crosby EC, Humphrey T, Lauer EW. *Correlative Anatomy of the Nervous System*. New York, NY: Macmillan Co; 1962.
35. Eberstaller O. *Das Stirnhirn: Ein Beitrag zur Anatomie der Oberfläche des Gehirns*. Wien-Leipzig, Germany: Urban & Schwarzenberg; 1890.
36. Lang J. *Klinische Anatomie des Kopfes*. Berlin, Germany: Springer Verlag; 1981.
37. Retzius G. *Das Menschenhirn: Studien zur Makroskopischen Morphologie*. Stockholm, Sweden: Norstedt; 1896.
38. Chi JG, Dooling EC, Gilles FH. Gyral development of the human brain. *Ann Neurol*. 1977;1:86-93.
39. Bailey P, von Bonin G, McCulloch WS. *Isocortex of the Chimpanzee*. Urbana: University of Illinois Press; 1950.
40. von Bonin G, Bailey P. *The Neocortex of Macaca mulatta*. Urbana: University of Illinois Press; 1947.
41. Yeni-Komshian GH, Benson DA. Anatomical study of cerebral asymmetry in the temporal lobe of humans, chimpanzees, and rhesus monkeys. *Science*. 1976;192:387-389.
42. Semendeferi K, Damasio H, Frank R, Van Hoesen GW. The evolution of the frontal lobes: a volumetric analysis based on three-dimensional reconstructions of magnetic resonance scans of human and ape brains. *J Hum Evol*. 1997;32:375-388.