



## UNILATERAL INDUCED NEOCORTICAL MALFORMATION AND THE FORMATION OF IPSILATERAL AND CONTRALATERAL BARREL FIELDS

G. D. ROSEN,\* H. WINDZIO and A. M. GALABURDA

Dyslexia Research Laboratory and Charles A. Dana Research Institute and Department of Neurology,  
Division of Behavioral Neurology, Beth Israel Deaconess Medical Center, 330 Brookline Avenue, Boston, MA 02215, USA  
Harvard Medical School, Boston, MA 02115, USA

**Abstract**—Freezing lesions to the developing cortical plate of rodents results in a focal malformation resembling human 4-layered microgyria, and this malformation has been shown to result in local and widespread disruptions of neuronal architecture, connectivity, and physiology. Because we had previously demonstrated that microgyria caused disruptions in callosal connections, we hypothesized that freeze lesions to the postero-medial barrel sub-field (PMBSF) in one hemisphere would affect the organization of this barrel field contralaterally. We placed freeze lesions in the presumptive PMBSF of neonatal rats and, in adulthood, assessed the architecture of the ipsilateral and contralateral barrel fields. Malformations in the PMBSF resulted in a substantial decrease in the number of barrels as identified by cytochrome oxidase activity. More importantly, we found an increase in the total area of the contralateral PMBSF, although there was no difference in individual barrel cross-sectional areas, indicating an increase in the area of inter-barrel septae.

This increase in the septal area of the contralateral PMBSF is consistent with changes in callosal and/or thalamic connectivity in the contralateral hemisphere. These results are another example of both local and widespread disruption of connective architecture following induction of focal microgyria. © 2001 IBRO. Published by Elsevier Science Ltd. All rights reserved.

*Key words:* microgyria, cerebral cortex, malformations, barrel, whisker.

Neocortical malformations have been associated with a wide variety of developmental disorders, including epilepsy and developmental dyslexia,<sup>11,13,44</sup> and these malformations can be induced in otherwise normal rodents through a variety of methods.<sup>2,7,38,39</sup> For example, freezing lesions to the developing cortical plate of rodents results in a focal malformation resembling human 4-layered microgyria.<sup>4–6,16,37,42</sup> This malformation is generally manifested as a focal infolding of the molecular layer of the neocortex forming a microsulcus (layer i), which is surrounded by a cell dense layer contiguous with layers II–III of the neocortex (layer ii). Below this layer is a cell-sparse region (layer iii), and a thin layer iv that is contiguous with the layer VIb (subplate cells) of the neocortex.

In addition to the local distortions of architecture that accompany freeze lesions, widespread effects on other aspects of anatomy, behavior, and neurophysiology

have been documented. Male rats with microgyria have difficulties, similar to those seen in individuals with dyslexia, in processing fast auditory stimuli.<sup>3,8–10,43</sup> Further, this defect in fast auditory processing correlates with a decrement in cell sizes in the medial geniculate nucleus<sup>8,15,35</sup> similar to that reported in dyslexia.<sup>12</sup> There are changes in excitatory and inhibitory receptors, both within and outside induced microgyria—*N*-methyl-D-aspartate (NMDA), alpha-amino-3-hydroxy-5-methyl-1,4 isoxazole propionic acid (AMPA) and kainate receptors are up-regulated, whereas gamma aminobutyric acid (GABA)<sub>A</sub> and GABA<sub>B</sub> receptors are down-regulated within the malformation. Outside of the microgyria, AMPA and kainate receptors are up-regulated, whereas GABA<sub>A</sub> is down-regulated.<sup>48</sup> Finally, slices of microgyric cortex have been shown to be epileptogenic—stimulation of the regions directly surrounding the microgyria (the ‘paramicrogyral zone’) result in epileptiform discharges in neocortex as far as 2–4 mm away from it.<sup>22,23,29,30</sup>

The mechanism whereby this induced focal malformation has such widespread effects on neuronal systems is not yet known, but changes in connectivity associated with developmental injury have been hypothesized to be one potentially important factor.<sup>17,18,34</sup> We have recently demonstrated remarkable changes in connectivity associated with microgyria. Specifically, we have seen an increase in heterotopic callosal projections associated with microgyria, in addition to a near complete absence

\*Correspondence to: G. D. Rosen, Department of Neurology, Division of Behavioral Neurology, Beth Israel Deaconess Medical Center, 330 Brookline Avenue, Boston, MA 02215, USA. Tel.: +1-617-667-3252; fax: +1-617-667-5217.

*E-mail address:* grosen@caregroup.harvard.edu (G. D. Rosen).

*Abbreviations:* AMPA, alpha-amino-3-hydroxy-5-methyl-1,4 isoxazole propionic acid; ANOVA, analysis of variance; CO, cytochrome oxidase; E, embryonic (gestational) age; NMDA, *N*-methyl-D-aspartate; P, postnatal age; PMBSF, postero-medial barrel sub-field; PMBSF<sub>i</sub>, ipsilateral PMBSF; PMBSF<sub>c</sub>, contralateral PMBSF; po, posterior nucleus of the thalamus.

of thalamocortical fibers within the microgyric region itself. In the paramicrogyral zone, we have seen very dense patches of thalamocortical fibers, which are thought to be responsible for the epileptogenic nature of microgyric cortex.<sup>34</sup>

In a recent report, Jacobs *et al.*<sup>24</sup> reported that a freeze lesion placed into the postero-medial barrel sub-field (PMBSF) of the rat resulted in substantial disruption of normal architecture of the field. Thus, while PMBSF normally contains 36 barrels [identified by cytochrome oxidase (CO) activity], these researchers found a significant decrease in the number of barrels (an average of 21) when freeze lesions were placed directly into the PMBSF. In addition, they found an increase in CO-activity in the paramicrogyral zone, and this area of CO increase was related to the epileptiform nature of the cortex. In contrast, qualitative examination of the PMBSF of the unlesioned hemisphere of lesioned animals did not reveal any differences from the comparable hemisphere in unlesioned controls.

Because microgyria disrupt the patterns of callosal connectivity, and there are callosal projections that innervate the regions between the barrels (septa) of the PMBSF,<sup>1,14,20,21</sup> we hypothesized that freeze lesions to the PMBSF in one hemisphere would affect the organization of this barrel field in the contralateral hemisphere, which might be best examined quantitatively. In this study, therefore, we induced microgyria in the PMBSF and qualitatively and quantitatively assessed the changes both in the damaged and undamaged hemispheres.

#### EXPERIMENTAL PROCEDURES

All efforts were made to minimize both the suffering and number of animals used in this experiment. All experimental procedures conformed to the standards of the Beth Israel Deaconess Medical Center's Institutional Animal Care and Use Committee.

Pregnant Wistar rats were obtained from Charles River Laboratories (Wilmington, MA) on gestational day 16–18 (E16–18). On the day after birth (P1), animals were randomly assigned to receive a freezing injury to the presumptive whisker barrel fields (PMBSF) of the left hemisphere or a sham surgery. In adulthood, (P60+) animals were perfused transcardially as described below, and their brains subsequently processed for cytochrome oxidase histochemistry. Barrel fields were drawn using a camera lucida in the lesioned and unlesioned hemispheres. These barrel fields were analysed qualitatively and quantitatively as outlined below.

#### Induction of microgyria

Microgyria were induced based on a modification of a technique by Dvorák and colleagues,<sup>4,5</sup> and reported in detail elsewhere.<sup>16,37</sup> Pups were anesthetized with hypothermia, and a small incision was made in the anteroposterior plane of the skin over the midline, exposing the skull. A cooled (–70°C) 2 mm diameter stainless steel probe was placed on the skull over the left hemisphere, approximately 2 mm lateral of the sagittal suture and 2 mm caudal of bregma for 5 s. Animals receiving sham surgery were treated identically to those receiving freezing injury except that the probe was maintained at room temperature. After surgery, the skin was quickly sutured, subjects were marked with identifying ink injections to the footpads, warmed under a lamp, and returned to their mother.

#### Histology

For all perfusions, subjects were anesthetized (pentobarbital, 60 mg/kg i.p.) and were transcardially perfused with 0.9% saline followed by 1.5% paraformaldehyde/2.5% glutaraldehyde. The brains were removed from the skulls and placed into fresh fixative for 24 h. The brains were then placed in a 10% sucrose solution in 0.1 M sodium phosphate buffer for at least 24 h, and then placed in 30% sucrose buffer until the brains sank. The location of the malformation was noted before the neocortical hemispheres were individually dissected and flattened between two glass slides and placed in dry ice for 2–4 h. The flattened hemispheres were sectioned tangentially on freezing microtome at 80 µm, and the sections were stored in 0.1 M sodium phosphate buffer. Every section (nine to 15 per brain) was stained for cytochrome oxidase using standard protocols.<sup>47</sup>

#### Analysis

All sections were analysed under light microscopy. Using a camera lucida attached to Zeiss Universal microscope, the barrel fields were drawn in both the lesioned and unlesioned hemispheres. For most subjects, the barrel fields were visible on more than one consecutive section. In order to align consecutive sections, both barrels and blood vessels were drawn on the initial section. After completing the tracing of these objects, adjacent sections were aligned using both the previously drawn barrels and blood vessels. All sections containing barrels were subsequently traced on the same piece of paper. The number of sections used to draw the barrel fields (two to four) did not differ between lesioned and control groups.

For quantitative analysis of microgyric animals, the area of each barrel of the contralateral PMBSF (PMBSF<sub>c</sub>) was measured using NIH Image. For sham animals we measured the PMBSF in both hemispheres. The area of the entire PMBSF<sub>c</sub> in lesioned rats, and the PMBSF in both hemispheres of controls was measured using the methods of Riddle and Purves.<sup>33</sup> In brief, this consisted of determining the centroid of each of the barrels along the outside border of the barrel field, and measuring the area of the polygon drawn connecting these centroids. Chi-square and ANOVA were used to statistically evaluate the data. The alpha level for all statistical tests was set at 0.05.

#### RESULTS

As expected, animals receiving a freezing injury to the cortical plate had obvious lesions when examined in adulthood. No malformations were noted in animals receiving sham surgery. An example of a typical malformation is illustrated in Fig. 1. The location of the lesions varied somewhat, and animals were categorized as to whether or not their lesions impinged on the ipsilateral PMBSF (PMBSF<sub>i</sub>). There were 12 animals with lesions in the PMBSF, three with lesions outside the PMBSF, and nine sham subjects.

#### Qualitative analysis

The appearance of barrel fields was normal in control animals. An example of a typical control section can be seen in Fig. 2.

*The ipsilateral postero-medial barrel sub-field is distorted.* As expected, there was substantial disruption of the barrel fields when the lesion was located within them. In some cases, there were no detectable barrels found in the tangentially cut sections. When individual barrels were present, it was difficult to assign them to any one particular barrel field (Fig. 3A). When lesions

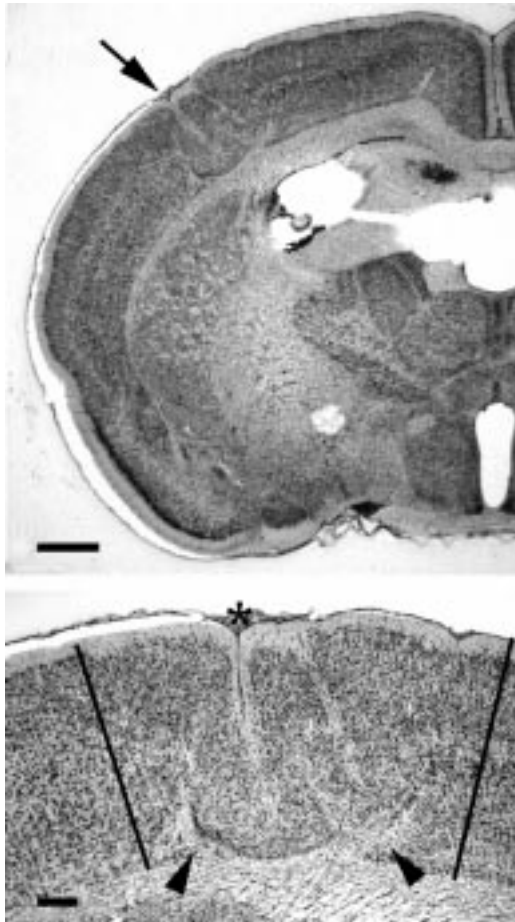


Fig. 1. Induced malformation. (A) Low power photomicrograph of a typical malformation (arrow) resulting from a freezing lesion to the developing cortical plate (arrow). (B) Higher power photomicrograph of same malformation with microsulcus (asterisk). Lines delineate border between malformed and normal cortex. Arrowheads indicate cell sparse lamina dissecans. Scale bar = 800  $\mu$ m (A); 200  $\mu$ m (B).

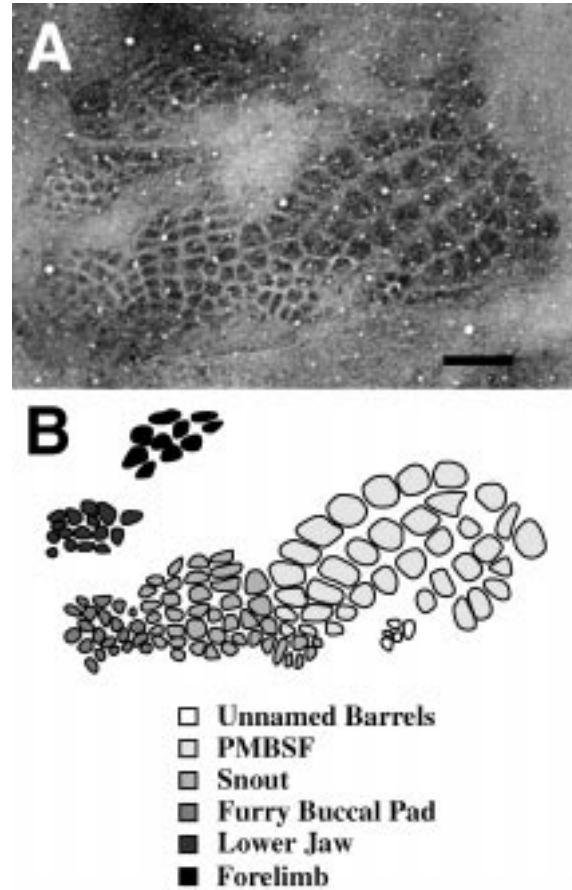


Fig. 2. CO activity in flattened section. Photomontage of flattened section stained for CO activity (A) and tracing (B) illustrating typical barrel fields in control subjects. Scale bar = 800  $\mu$ m

occurred outside the PMBSF<sub>i</sub>, there was little noticeable disruption of any of the barrel field (Fig. 3B).

There are areas of increased cytochrome oxidase density in layer ii of the microgyria. In the regions surrounding the microsulcus, there was a uniform increased density of CO, compared to background, that was visible throughout its depth, and that corresponded to layer ii of the microgyrus (Fig. 4). We confirmed this by sectioning an additional three microgyric brains in the coronal plane and reacting the tissue for CO as can be seen in Fig. 5. Unlike the control subjects, where staining in layer IV is punctuated by regular periods of increased CO density, CO activity in the lesioned subjects was uniformly dense.

*Quantitative analysis*

All quantitative analysis was undertaken on the PMBSF in the right hemisphere, i.e., the hemisphere contralateral to the malformation (PMBSF<sub>c</sub>). We chose to examine the PMBSF because it has previously been shown to be susceptible to developmental intervention (e.g. Refs 19, 27, 31, 40).

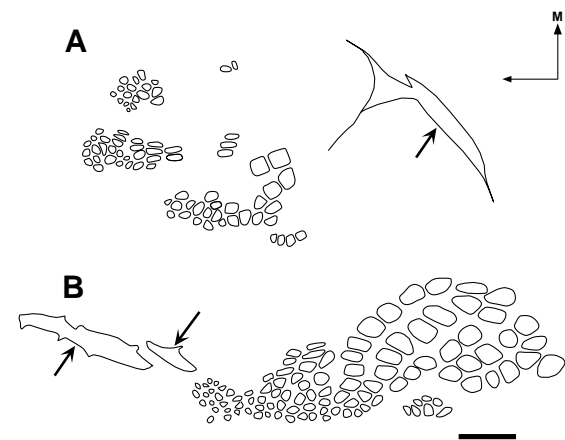


Fig. 3. Malformations within and outside PMBSF<sub>i</sub>. (A) Drawing of barrel fields from brain with malformation (arrow) located within the PMBSF. Note a near complete absence of all barrels in the PMBSF<sub>i</sub>. (B) Drawing of barrel fields from brain with malformation located outside the PMBSF<sub>i</sub>. In contrast, these malformations (arrows) do not disturb the normal pattern of barrel formation in the PMBSF<sub>i</sub>. Orientation arrows: M, media; A, anterior. Scale bar = 1 mm.

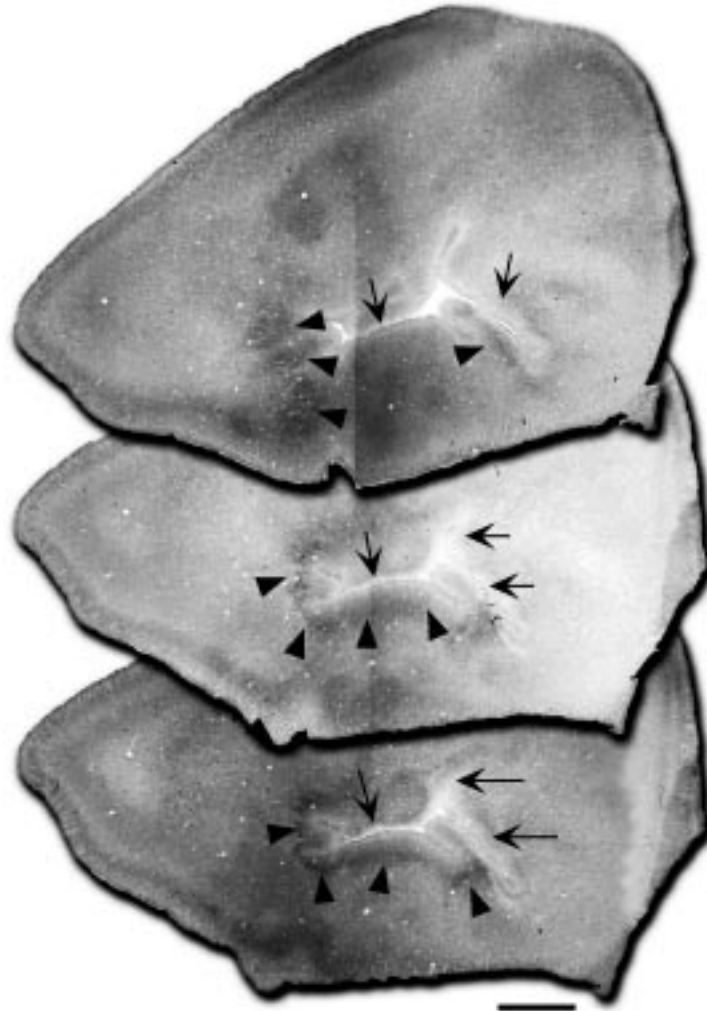


Fig. 4. CO activity associated with a malformation. Three sections from one subject with an induced malformation (arrows) in the PMBSF<sub>i</sub>. There are patches of dense CO staining (arrowheads), but few, if any barrels visible. Scale bar = 800  $\mu$ m.

*There are missing barrels in the contralateral postero-medial barrel sub-field.* The PMBSF has a well-defined structure consisting of 36 individual barrels in five rows (Fig. 6A). Of the 12 animals with lesions to the PMBSF<sub>i</sub>, five had at least one barrel missing from the PMBSF<sub>c</sub>. In contrast, there was a single subject with just one barrel missing from the 18 control hemispheres. This difference in distribution was significant ( $\chi^2 = 6.62$ ,  $df = 1$ ,  $P < 0.05$ ). Of the three animals with malformations located outside of the barrel fields, there was one subject with a single missing barrel in the PMBSF<sub>c</sub>. This distribution did not differ from either of the other groups (Fig. 6).

*There is no difference in individual barrel area measurements in the contralateral postero-medial barrel sub-field between microgyric and sham animals.* We analysed the area of individual barrels within the whisker barrel field using a one-way ANOVA, with Lesion (PMBSF, Outside PMBSF, Sham) as the independent measure. We found no significant differences among the independent measures for any of the individual barrel areas. We also performed a one-way ANOVA with

Lesion dichotomized as either PMBSF or Sham, and again there were no significant differences. Finally, we performed a repeated measures ANOVA, with 'Lesion' as the between factor and 'Barrels' as within factors. Although there were significant differences between the individual barrels, there were no main effects of Lesion, nor were there any interactions with Lesion. These results are summarized in Fig. 7.

*The total contralateral postero-medial barrel sub-field area is larger in animals with microgyria in the ipsilateral postero-medial barrel sub-field.* Having found no differences in the area of individual barrels in the whisker barrel field, we then measured the area of the entire barrel field. Animals with missing barrels were excluded from this analysis, thereby reducing the number of control hemispheres to 17 and the lesioned animals to seven. We analysed these data using a one-way ANOVA, with Lesion (PMBSF, Sham) as the independent measure. There was a significant effect of Lesion ( $F_{2,24} = 4.85$ ,  $P < 0.05$ ). The area of the PMBSF<sub>c</sub> in animals with lesions was significantly greater than that

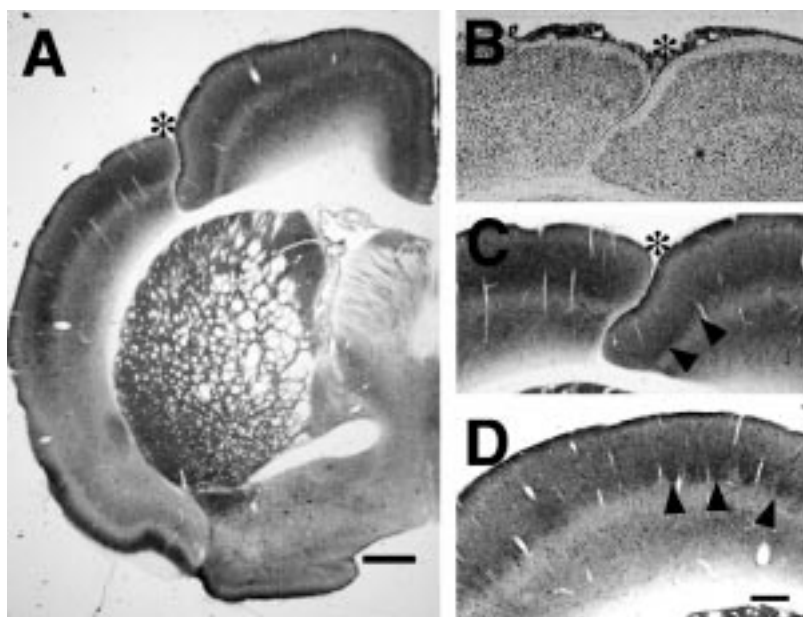


Fig. 5. CO activity in layer II of the microgyric malformation. (A) Low power photomicrograph of coronally-sectioned CO-stained subject with induced malformation (asterisk). (B) Adjacent nissl-stained section. (C) Higher power photomicrograph of malformation showing a continuous stripe of dense CO activity (arrowheads). (D) CO-stained section from control subject showing typical barrel formation (patches of increased CO density). Scale bar = 800  $\mu\text{m}$  (A); 400  $\mu\text{m}$  (B–D).

of shams ( $x \pm \text{S.E.M.} = 4.22 \pm 0.29$  vs  $3.76 \pm 0.07$ , respectively). These results are summarized in Fig. 8.

*Extent of lesion in ipsilateral postero-medial barrel sub-field does not affect quantitative measures.* The question of whether the extent of damage to the PMBSF<sub>i</sub> could affect quantitative measures in the PMBSF<sub>c</sub> was difficult to address. As described above, the effect of the freezing injury on the PMBSF<sub>i</sub> was quite extensive, and quantitation of the amount of damage was impossible. In an attempt to gauge the degree of damage, we categorized lesioned subjects as to whether there were or were not visible barrels remaining in the PMBSF<sub>i</sub>. Of the 12 subjects, four had at least one (but no more than 10) barrels present. We then re-analysed the data of the lesioned subjects using a one-way ANOVA with this categorized variable as the independent measure. We found no difference in either the area of the individual barrels themselves or in the PMBSF<sub>c</sub> as a whole.

## DISCUSSION

### *Changes to ipsilateral postero-medial barrel sub-field*

We found changes in the ipsilateral and contralateral PMBSF. Our findings in the ipsilateral hemisphere are similar to those previously reported.<sup>24</sup> As with the previous report, we found that freeze lesions placed into the PMBSF<sub>i</sub> severely disrupted the formation of barrels (as identified by CO activity) in that field. We also noted the increase in CO-activity in the regions surrounding the malformation, and showed that this increase in CO-activity can be seen in layer II of the microgyrus.

There were significant differences between our findings

in the PMBSF<sub>i</sub> and those of Jacobs *et al.*<sup>24</sup> For example, we found a much greater degree of disruption, with most of our cases showing little or no evidence of barrel formation and none having more than 10 barrels. In contrast, Jacobs *et al.* report the mean number of barrels as  $21 \pm 2.4$ . There are a number of possible explanations for this discrepancy. It could be an issue of sensitivity of CO staining, with our method yielding lower contrast between regions of CO activity and background and therefore making barrel identification difficult. We do not consider this a likely explanation as we show similar patterns of staining of control brains, as well as dense staining of barrels outside the PMBSF<sub>i</sub>. Another possibility is one of lesion selection. We strictly limited our analysis to those lesions that were placed directly in the center of the PMBSF<sub>i</sub>, and it is not clear whether this strict selection also applied to the previous report. Finally, it could be that our freeze lesions resulted in more severe malformations than those of Jacobs *et al.*, and that these larger malformations had more drastic effects on the local barrel field. Comparison of lesion size from previous publications from this group, as well direct examination of their tissue,<sup>36</sup> support this possibility.

### *Changes to the contralateral postero-medial barrel sub-field*

In the previous report, Jacobs *et al.*<sup>24</sup> reported that the appearance of the PMBSF<sub>c</sub> was normal. This was strictly a qualitative statement. We performed a quantitative analysis and found two differences between the PMBSF<sub>c</sub> and those of control brains: First, we found missing barrels in the PMBSF in five of 12 subjects with lesions in the PMBSF, compared to only one of 18 control

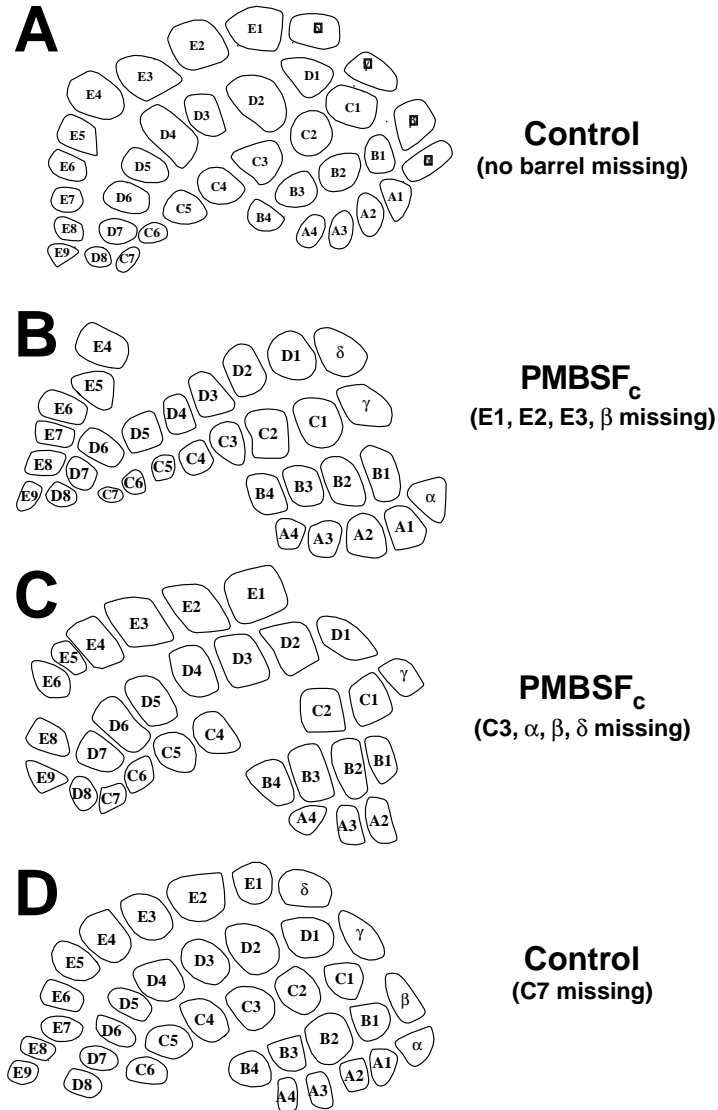


Fig. 6. Missing barrels in the PMBSF. (A) Drawing of PMBSF<sub>c</sub> from control subject with each barrel labeled using standard designations. (B) Drawing of PMBSF<sub>c</sub> from subject with missing barrels in the periphery of the field. (C) Drawing of PMBSF<sub>c</sub> from a subject with a missing barrel in the center of the field. (D) Drawing of PMBSF from the one control subject with a single missing barrel.

hemispheres. This was an unexpected finding and one that, despite the statistical significance, is difficult to interpret. Specifically, it is impossible to rule out technical issues playing a role. While the CO method is time-tested, it has been useful only to show positive activity—the lack of CO activity has not classically been used as a definitive diagnostic demonstration of absence of structure and function. When there are large areas of absent CO-activity (as in the PMBSF of the lesioned hemisphere), it is easier to accept the lack of a positive stain as meaning an absence of barrels. When single barrels are unexpectedly missing, however, it becomes harder to unequivocally rule out artifact. It is true that only one barrel was missing in all the control hemispheres, but replication of these findings using other stains (such as succinic dehydrogenase) would give us greater confidence in these results.<sup>33</sup> In addition, examination of

barreloids in the ventrobasal thalamus may shed light on this issue.<sup>28,41</sup>

We also found an increase in the overall area of the PMBSF<sub>c</sub> in comparison to control PMBSF. This is despite the fact that there was no difference in the size of the individual barrels of the PMBSF between controls and lesioned animals. A possible explanation for this difference could be that the changes in the size of the PMBSF<sub>c</sub> reflect generalized changes to the entire brain as a result of the freezing injury. For example, it could be that the entire brain is larger in microgyric subjects when compared to controls. Although we did not measure brain weight in these subjects, we have done so in subsequent studies, and have found a significant decrease in brain weight in microgyric subjects (unpublished observations), and this decrease is seen at all developmental ages and in both sexes. It is therefore unlikely that the

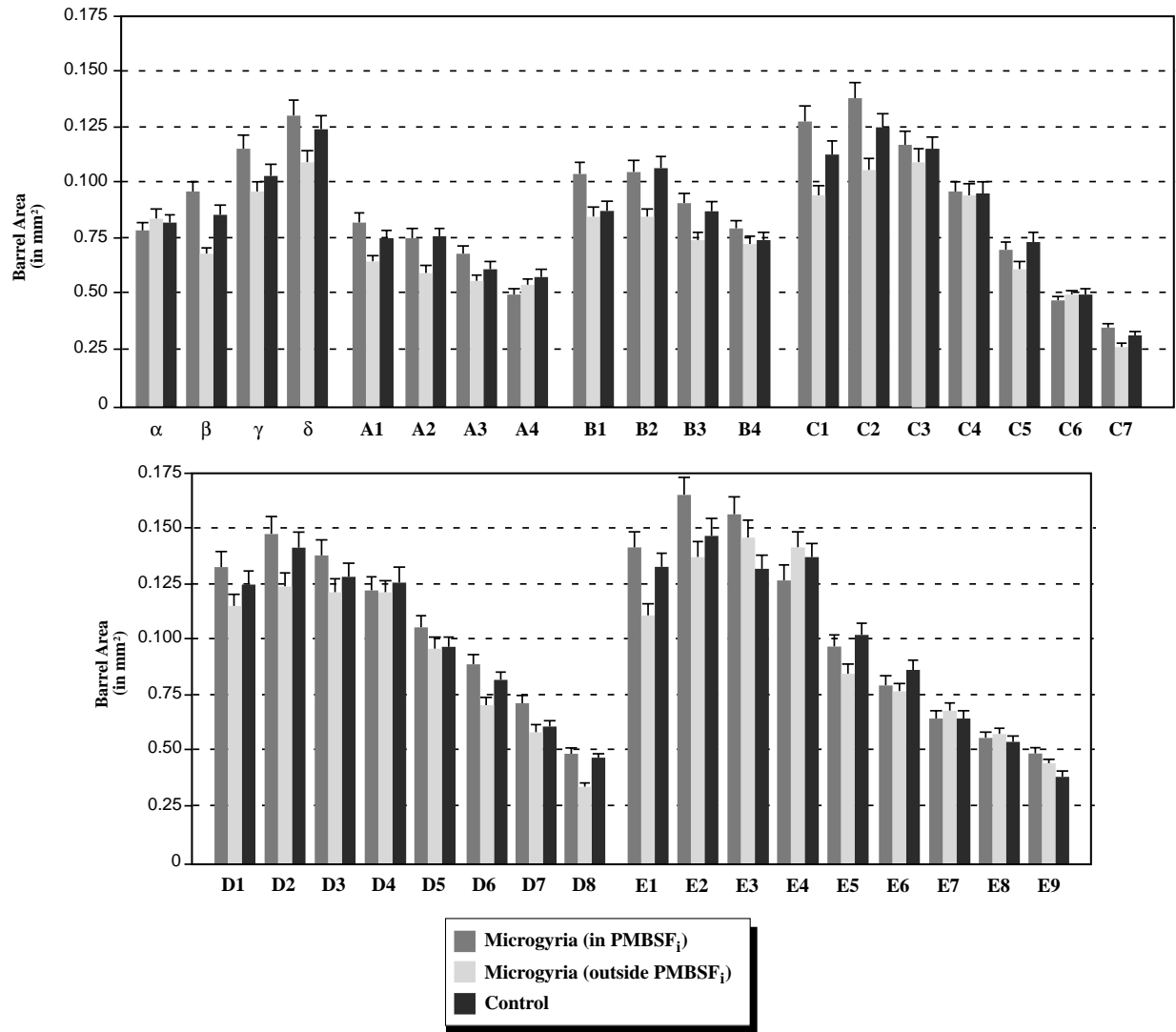


Fig. 7. Mean size of individual PMBSF<sub>c</sub> barrels. Histograms showing the mean (and S.E.M.) area of each of the barrels for subjects with lesions within the PMBSF<sub>i</sub> (measures of contralateral barrels,  $n = 10-12$ ), those with lesions outside the PMBSF<sub>i</sub> (measures of contralateral barrels,  $n = 2$  or 3), and controls (both hemispheres,  $n = 17$  or 18). There are no significant differences among the three groups. The number of animals vary because of missing barrels.

increase in the PMBSF<sub>c</sub> we report here reflects more generalized changes in brain size. Because of this, we argue that if there is no difference in individual barrel size, and that overall changes in brain size are in the opposite direction from those seen in the PMBSF<sub>c</sub>, then the only explanation for the larger total area of the contralateral PMBSF is that the distance between the barrels is greater.

If the inter-barrel distance is larger, why is it so? We hypothesize that it may reflect changes in connectivity. Individual barrels in the PMBSF represent individual whiskers, and the topography of the PMBSF matches the pattern of whiskers on the snout.<sup>32,45</sup> The barrels are densely innervated by thalamocortical fibers from the medial division of the ventral basal nucleus.<sup>25,46</sup> Callosal connections, as well as those from the posterior nucleus (PO), however, are absent in the barrels themselves, but are densest in the septa separating the barrels.<sup>1,14,20,21,26</sup> In

the current experiment, therefore, we postulate that the increase in size of PMBSF<sub>c</sub> reflects increases in cortico-thalamic projections from PO and/or callosal connectivity.

As described above, there is evidence to suggest that microgyria disrupts connections between the cortex and thalamus as well as between the two hemispheres.<sup>34</sup> Thus, we reported the presence of heterologous, as well as a diminution or absence of homologous, connections to the opposite hemisphere following induction of microgyria into various components of the somatosensory cortex. It could be that this decrease in homotopic callosal projections could lead to an increase in PO connections in the vacated space. As yet, however, we have no direct evidence of specific changes in thalamocortical or cortico-cortical connections that are disrupted following lesions of the PMBSF solely. Future experiments will address this issue.

It should be mentioned that the range of values for

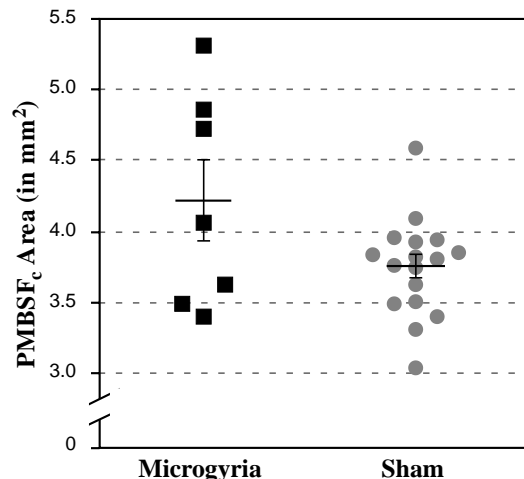


Fig. 8. Total PMBSF<sub>c</sub> area in lesioned and control subjects. Scatterplot of total PMBSF<sub>c</sub> areas for subjects with lesions in the PMBSF<sub>i</sub> and controls. Error bars indicated means  $\pm$  S.E.M.. The PMBSF<sub>c</sub> of lesioned subjects are significantly larger than the controls ( $P < 0.05$ ).

the area of the PMBSF is about 10–15% less than those reported previously.<sup>33</sup> This relatively small discrepancy is most likely due to differences in rodent strain, fixation, and/or histochemistry. It is important to note that all subjects in the current experiment were treated identically, and changes in PMBSF areas were not likely to be related to issues of differential tissue shrinkage.

## CONCLUSIONS

Placement of a freeze lesion into the PMBSF causes changes to the architecture of this barrel field as well as to the contralateral barrel field. We have replicated previous results that demonstrated a significant distortion of the PMBSF<sub>i</sub> following neonatal freeze lesions placed with it. If anything, in our hands the disruption of the PMBSF<sub>i</sub> appears to be even greater than previously described. This distortion consists of a near absence of barrels as denoted by CO activity, and dense areas of continuous, as opposed to punctate, CO activity in layer ii of the microgyrus. We have also found an increase in the area of the PMBSF<sub>c</sub>, when compared with those of controls, despite the fact that there are no differences in size of individual barrels. We hypothesize that this difference in PMBSF<sub>c</sub> reflects changes occurring in the inter-barrel septae, a region known to contain projections from ipsilateral PO and contralateral homotopic cortex. Taken together, these results lend further support to the notion that focal induced malformations can result in widespread distortions of neuronal architecture.

*Acknowledgements*—This work was supported, in part, by grant HD 20806 from the Public Health Service of the USA. The authors wish to acknowledge the technical support of Alison Frank.

## REFERENCES

- Akers R. M. and Killackey H. P. (1978) Organization of corticocortical connections in the parietal cortex of the rat. *J. comp. Neurol.* **181**, 513–538.
- Brunstrom J. E., Gray-Swain M. R., Osborne P. A. and Pearlman A. L. (1997) Neuronal heterotopias in the developing cerebral cortex produced by neurotrophin-4. *Neuron* **18**, 505–517.
- Clark M. G., Rosen G. D., Tallal P. and Fitch R. H. (2000) Impaired two-tone processing at rapid rates in male rats with induced microgyria. *Brain Res.* **871**, 94–97.
- Dvorák K. and Feit J. (1977) Migration of neuroblasts through partial necrosis of the cerebral cortex in newborn rats—contribution to the problems of morphological development and developmental period of cerebral microgyria. *Acta neuropath. Berlin* **38**, 203–212.
- Dvorák K., Feit J. and Juránková Z. (1978) Experimentally induced focal microgyria and status verrucosus deformis in rats—Pathogenesis and interrelation histological and autoradiographical study. *Acta neuropath. Berlin* **44**, 121–129.
- Ferrer I., Alcántara S., Catala I. and Zújar M. J. (1993) Experimentally induced laminar necrosis, status verrucosus, focal cortical dysplasia reminiscent of microgyria, and porencephaly in the rat. *Expl Brain Res.* **94**, 261–269.
- Ferrer I., Alcántara S., Zújar M. J. and Cinós C. (1993) Structure and pathogenesis of cortical nodules induced by prenatal x-irradiation in the rat. *Acta neuropath. Berlin* **85**, 205–212.
- Fitch R. H., Brown C. P., Tallal P. and Rosen G. D. (1997) Effects of sex and MK-801 on auditory-processing deficits associated with developmental microgyric lesions in rats. *Behav. Neurosci.* **111**, 404–412.
- Fitch R. H. and Tallal P. (1995) Neurobiology of speech perception. *A. Rev. Neurosci.* **20**, 331–353.
- Fitch R. H., Tallal P., Brown C., Galaburda A. M. and Rosen G. D. (1994) Induced microgyria and auditory temporal processing in rats: A model for language impairment? *Cereb. Cortex* **4**, 260–270.
- Galaburda A. M. and Kemper T. L. (1979) Cytoarchitectonic abnormalities in developmental dyslexia; a case study. *Ann. Neurol.* **6**, 94–100.
- Galaburda A. M., Menard M. T. and Rosen G. D. (1994) Evidence for aberrant auditory anatomy in developmental dyslexia. *Proc. natn. Acad. Sci. USA* **91**, 8010–8013.
- Galaburda A. M., Sherman G. F., Rosen G. D., Aboitiz F. and Geschwind N. (1985) Developmental dyslexia: Four consecutive cases with cortical anomalies. *Ann. Neurol.* **18**, 222–233.
- Hayama T. and Ogawa H. (1997) Regional differences of callosal connections in the granular zones of the primary somatosensory cortex in rats. *Brain Res. Bull.* **43**, 341–347.
- Herman A. E., Galaburda A. M., Fitch H. R., Carter A. R. and Rosen G. D. (1997) Cerebral microgyria, thalamic cell size and auditory temporal processing in male and female rats. *Cereb. Cortex* **7**, 453–464.
- Humphreys P., Rosen G. D., Press D. M., Sherman G. F. and Galaburda A. M. (1991) Freezing lesions of the newborn rat brain: A model for cerebrocortical microgyria. *J. Neuropath. exp. Neurol.* **50**, 145–160.
- Innocenti G. M. and Berbel P. (1991) Analysis of an experimental cortical network: i) Architectonics of visual areas 17 and 18 after neonatal injections of ibotenic acid; similarities with human microgyria. *J. Neurol. Transplant* **2**, 1–28.
- Innocenti G. M. and Berbel P. (1991) Analysis of an experimental cortical network: ii) Connections of visual areas 17 and 18 after neonatal injections of ibotenic acid. *J. Neurol. Transplant* **2**, 29–54.
- Ito M. (1995) Barrelfield of the prenatally X-irradiated rat somatosensory cortex: a histochemical and electrophysiological study. *J. comp. Neurol.* **352**, 248–262.

20. Ivy G. O., Gould H. J. and Killackey H. P. (1984) Variability in the distribution of callosal projection neurons in the adult rat parietal cortex. *Brain Res.* **306**, 53–61.
21. Ivy G. O. and Killackey H. P. (1981) The ontogeny of the distribution of callosal projection neurons in the rat parietal cortex. *J. comp. Neurol.* **195**, 367–389.
22. Jacobs K. M., Gutnick M. J. and Prince D. A. (1996) Hyperexcitability in a model of cortical maldevelopment. *Cereb. Cortex.* **6**, 514–523.
23. Jacobs K. M., Hwang B. J. and Prince D. A. (1999) Focal epileptogenesis in a rat model of polymicrogyria. *J. Neurophysiol.* **81**, 159–173.
24. Jacobs K. M., Mogensen M., Warren E. and Prince D. A. (1999) Experimental microgyri disrupt the barrel field pattern in rat somatosensory cortex. *Cereb. Cortex.* **9**, 733–744.
25. Killackey H. P. and Leshin S. (1975) The organization of specific thalamocortical projections to the posteromedial barrel subfield of the rat somatic sensory cortex. *Brain Res.* **86**, 469–472.
26. Koralek K. A., Jensen K. F. and Killackey H. P. (1988) Evidence for two complementary patterns of thalamic input to the rat somatosensory cortex. *Brain Res.* **463**, 346–351.
27. Koralek K. A. and Killackey H. P. (1990) Callosal projections in rat somatosensory cortex are altered by early removal of afferent input. *Proc. natn. Acad. Sci., USA* **87**, 1396–1400.
28. Land P. W. and Akhtar N. D. (1987) Chronic sensory deprivation affects cytochrome oxidase staining and glutamic acid decarboxylase immunoreactivity in adult rat ventrobasal thalamus. *Brain Res.* **425**, 178–181.
29. Luhmann H. J. and Raabe K. (1996) Characterization of neuronal migration disorders in neocortical structures. I. Expression of epileptiform activity in an animal model. *Epilepsy Res.* **26**, 67–74.
30. Luhmann H. J., Raabe K., Qü M. and Zilles K. (1998) Characterization of neuronal migration disorders in neocortical structures: extracellular in vitro recordings. *Eur. J. Neurosci.* **10**, 3085–3094.
31. Micheva K. D. and Beaulieu C. (1995) An anatomical substrate for experience-dependent plasticity of the rat barrel field cortex. *Proc. natn. Acad. Sci., USA* **92**, 11,834–11,838.
32. Rice F. L., Gomez C., Barstow C., Burnet A. and Sands P. (1985) A comparative analysis of the development of the primary somatosensory cortex: Interspecies similarities during barrel and laminar development. *J. comp. Neurol.* **236**, 477–495.
33. Riddle D. R. and Purves D. (1995) Individual variation and lateral asymmetry of the rat primary somatosensory cortex. *J. Neurosci.* **15**, 4184–4195.
34. Rosen G. D., Burstein D. and Galaburda A. M. (2000) Changes in efferent and afferent connectivity in rats with cerebrocortical microgyria. *J. comp. Neurol.* **418**, 423–440.
35. Rosen G. D., Herman A. E. and Galaburda A. M. (1999) Sex differences in the effects of early neocortical injury on neuronal size distribution of the medial geniculate nucleus in the rat are mediated by perinatal gonadal steroid. *Cereb. Cortex* **9**, 27–34.
36. Rosen G. D., Jacobs K. M. and Prince D. A. (1998) Effects of neonatal freeze lesions on expression of parvalbumin in rat neocortex. *Cereb. Cortex.* **8**, 753–761.
37. Rosen G. D., Press D. M., Sherman G. F. and Galaburda A. M. (1992) The development of induced cerebrocortical microgyria in the rat. *J. Neuropath. exp. Neurol.* **51**, 601–611.
38. Rosen G. D., Sherman G. F., Richman J. M., Stone L. V. and Galaburda A. M. (1992) Induction of molecular layer ectopias by puncture wounds in newborn rats and mice. *Devl Brain Res.* **67**, 285–291.
39. Schmidt S. and Lent R. (1987) Effects of prenatal irradiation on the development of cerebral cortex and corpus callosum of the mouse. *J. comp. Neurol.* **264**, 193–204.
40. Simons D. J., Durham D. and Woolsey T. A. (1984) Functional organization of mouse and rat smQ barrel cortex following vibrissal damage on different postnatal days. *Somatosensory Res.* **1**, 207–245.
41. Sugitani M., Yano J., Sugai T. and Ooyama H. (1990) Somatotopic organization and columnar structure of vibrissae representation in the rat ventrobasal complex. *Expl Brain Res.* **81**, 346–352.
42. Suzuki M. and Choi B. H. (1991) Repair and reconstruction of the cortical plate following closed cryogenic injury to the neonatal rat cerebrum. *Acta neuropath. Berlin* **82**, 93–101.
43. Tallal P. and Piercy M. (1973) Defects of non-verbal auditory perception in children with developmental aphasia. *Nature* **241**, 468–469.
44. Taylor D. C., Falconer M. A., Bruton C. J. and Corsellis J. A. N. (1971) Focal dysplasia of the cerebral cortex in epilepsy. *J. Neurol. Neurosurg. Psychiat.* **34**, 369–387.
45. Welker C. and Woolsey T. A. (1974) Structure of layer IV in the somatosensory neocortex of the rat: description and comparison with the mouse. *J. comp. Neurol.* **158**, 437–454.
46. White E. L. and Deamicus R. A. (1977) Afferent and efferent projections of the region in mouse SM-I cortex which contains the posteromedial barrel subfield. *J. comp. Neurol.* **175**, 455–482.
47. Wong-Riley M. (1979) Changes in the visual system of monocularly sutured or enucleated cats demonstrable with cytochrome oxidase histochemistry. *Brain Res.* **171**, 11–28.
48. Zilles K., Qü M., Schleicher A. and Luhmann H. J. (1998) Characterization of neuronal migration disorders in neocortical structures: quantitative receptor autoradiography of ionotropic glutamate, GABA(A) and GABA(B) receptors. *Eur. J. Neurosci.* **10**, 3095–3106.

(Accepted 18 January 2001)